
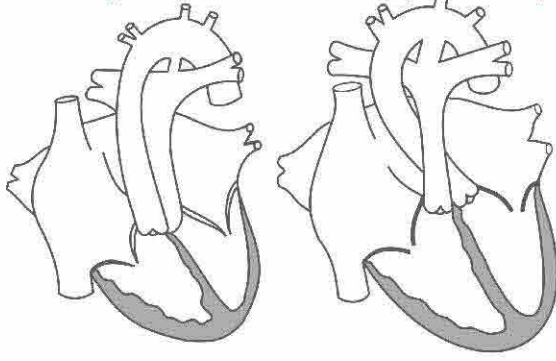


**Conotruncal abnormalities**  
**Tips for diagnosis in the fetus**



Marcin Wiechec MD  
University Hospital in Krakow


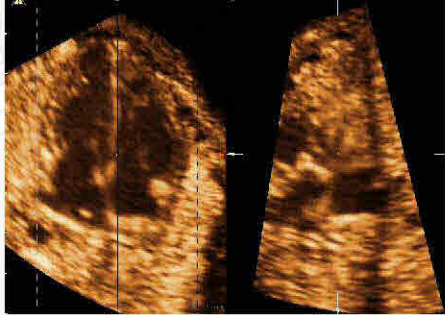
**Transposition of GA (d-TGA)**



**Transposed Great Arteries**



**Normal heart**



**TGA**



**TGA in segments**

